



July 2016

Published by Global Dental Implant Academy

# G DIA

## Dental Implant CASE REPORT

## Rehabilitation of A Non-Restorable Maxillary Central Incisor Tooth for Function and Esthetic Utilizing An Immediate Placement and Provisionalization Protocol



### Jin Y. Kim, DDS, MPH, MS, FACD

Dr. Jin Y. Kim is a dual board-certified periodontist. He is a diplomate of the American Board of Periodontology (ABP), American Board of Oral Implantology / Implant Dentistry (ABOI / ID), and of the International Congress of Oral Implantologists (ICOI). Jin is also a fellow of American Academy of Implant Dentistry (AAID), and an inducted fellow of the American College of Dentists (ACD). He is the co-founder and program director of Global Dental Implant Academy (GDIA) and operates private practices in Diamond Bar and Garden Grove, California, USA.

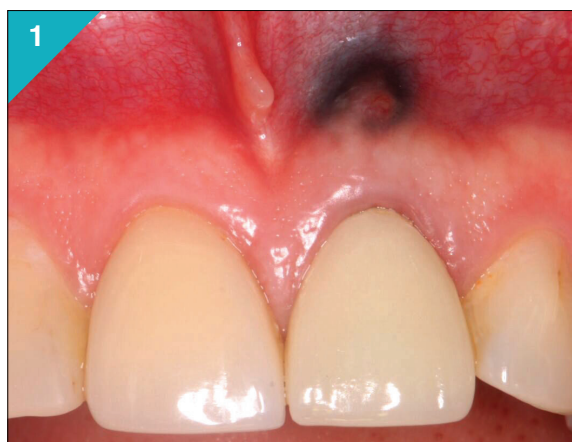

Figure 1. Pre-treatment clinical view.

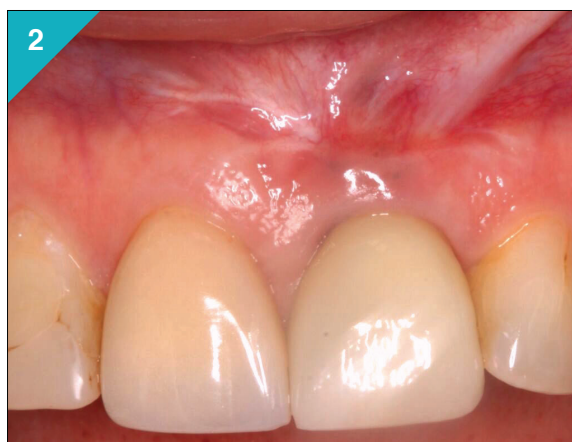


Figure 2. Post-treatment clinical view.

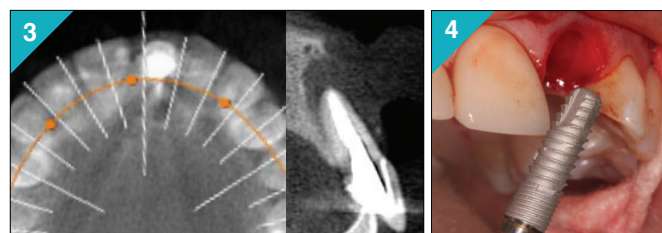


Figure 3. Cross-sectional CT of upper left central incisor.

Figure 4. DENTIS™ implant being placed into the prepared socket site.

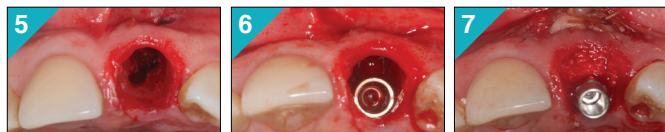
### Case History

A healthy 47-years old female patient presented with fracture of a endodontically treated upper central incisor tooth. The tooth had a history of apical surgery that did not resolve well. A CT study revealed significant bone destruction at the peri-apical region as well as the major portion of the facial bone plate. Patient desired to have the amalgam tattoo from previous surgery removed. Immediate implant placement into the extraction socket, non-functional implant tooth (NFIT), and use of autologous biologic enhancers were used with a “poncho” technique, and custom impression technique, followed by milled titanium abutment was utilized to make this unique case a clinical success.



## Implant Surgery

In a single surgery, under intravenous conscious sedation anesthesia, the tooth was removed without raising a sulcular flap. There was a thin bridge of buccal bone close to the gingival margin, which was to be preserved at all cost. An internal hexed, conical connection implant (4.3mm x 14mm, DENTIS™ s-Clean) was placed towards the palatal part of the socket, hugging the palatal lamina dura of the socket. Implant site preparation was carried out with ultrasonic piezoelectric surgery device (Surgybone™) and rotary drills. Primary stability was obtained by apical engagement of the long implant. Implant stability was recorded at 61 ISQ (implant stability quotient) on Ostell™ device.

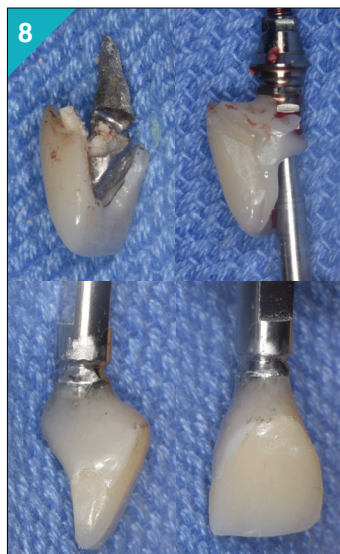


**Figure 5.** Osteotomy completed in the socket.

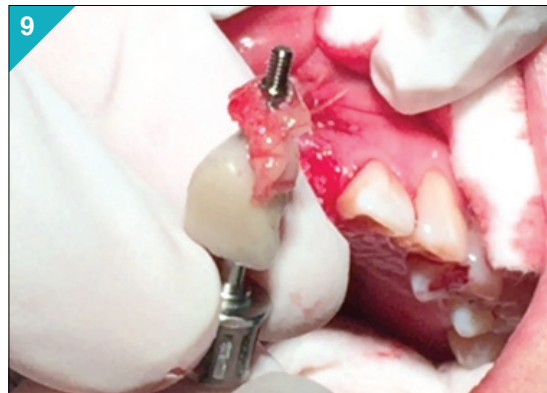
**Figure 6.** Implant securely placed in the palatal aspect of the socket.

**Figure 7.** Socket and facial defect is grafted with “sticky bone,” and CGF membrane.

Immediate provisional restoration was constructed with the porcelain portion of the extracted tooth and a hexed titanium abutment, bonded with light-cured composite resin. This restoration was kept out of occlusion, and patient was instructed to avoid chewing on the front teeth.



**Figure 8.** Non-functional implant tooth(NFIT) is being made with retrieved porcelain tooth, a titanium abutment, and light cured resin.



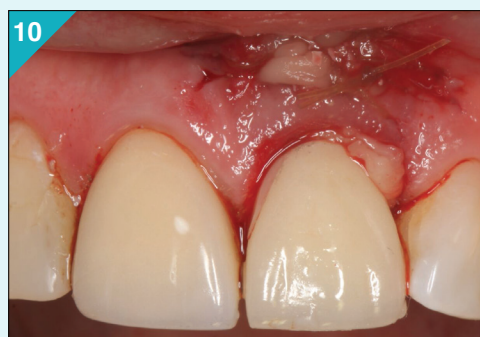**Figure 9.** Immediately prior to installing the NFIT, a double layer of CGF was pierced by the restoration for a “poncho technique” of delivery.

The remaining soft and hard tissue defect, including the vestibular area with amalgam tattooed soft tissue was excised widely. This area was grafted with “sticky bone” and CGF (Concentrated Growth Factors, Medifuge™).

“Sticky bone” was made with xenograft (Bio-Oss™) and mineralized allograft (LifeNet™). In order to seal the gingival margin with graft material and to enhance healing potential, a double layer of CGF was pierced through the NFIT restoration immediately before it’s installation.

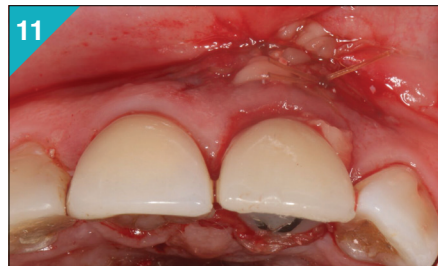
This “poncho technique” of delivering CGF assured secure placement of the biologic enhancer, exactly where it was needed, at the edge of the gingival margin, without the use of conventional sutures. The mass of CGF at the tattoo site was secured with 4.0 chromic gut sutures.

### Series of Clinical Views

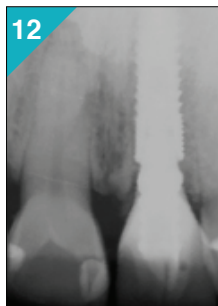


**Figure 10.** Clinical presentation, immediate post-surgery, showing stable placement of all graft material, and the NFIT.

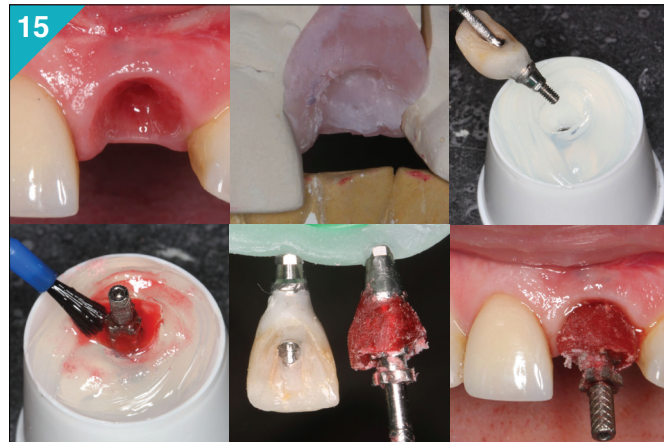



**Figure 11.** Immediate post-surgery view shows over grafting of the buccal ridge to compensate for future post-surgical contraction.



**Figure 12.** Post-surgical peri-apical (PA) radiograph.

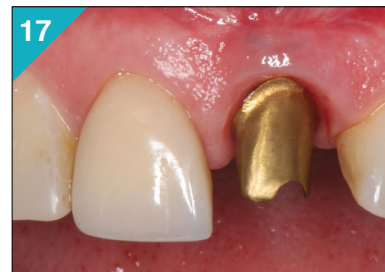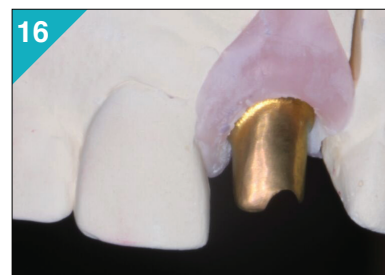


**Figure 15.** Custom impression technique, using duplicated contours of NFIT as a custom impression coping.

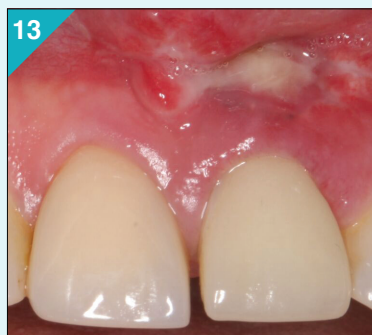## Restorative Phase

Approximately 3 months after the surgery, NFIT was removed and the ISQ remeasured. It recorded 76, representing a 15-point increase. Definitive restorative work commenced with customized impression technique to accurately record and convey the 3D peri-implant tissue contour to the dental laboratory. A milled titanium abutment was fabricated, and a layer of gold hue titanium nitrate coating was applied by electroplating technique.

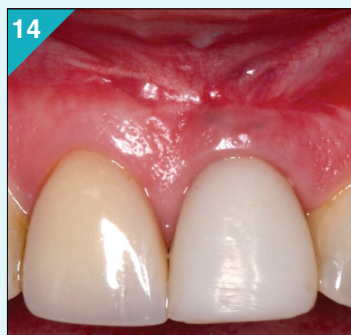The custom abutment and resin provisional restoration was installed at 6-months post-surgery. Porcelain fused to metal full coverage restoration was fabricated and delivered at 12-months post-surgery, after allowing a 6-month period of tissue maturation.



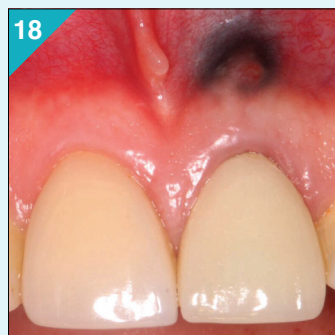**Figure 16 & Figure 17.** Custom milled abutment.



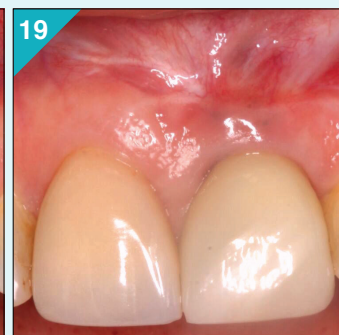**Figure 13.** Healing at 2-weeks.

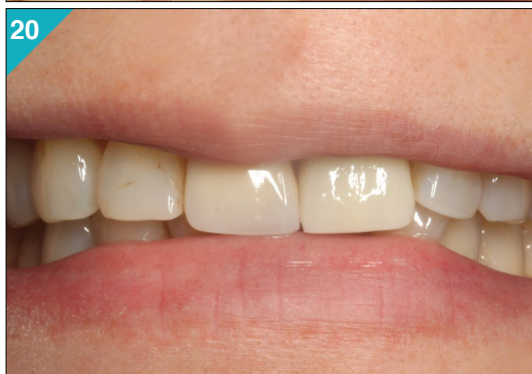
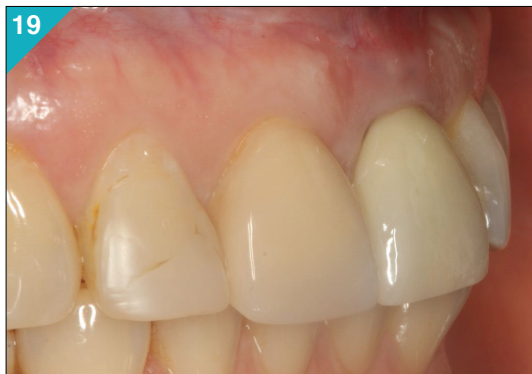
**Figure 14.** Healing at 6-months.

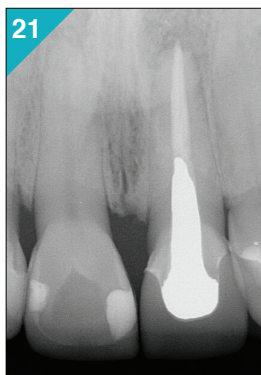


**Figure 18 & 19.** Comparison of pre- and post-treatment (at 12-months).

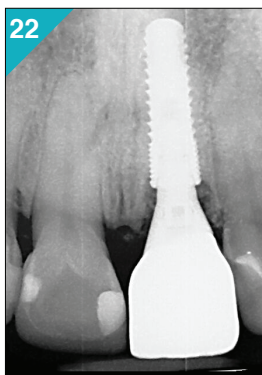




**Figure 19 & 20.** Full restoration of function and esthetics was achieved in this case, with a highly satisfied and compliant patient.



**Figure 21.** Pre-treatment PA.



**Figure 22.** Post-treatment PA.

## References

1. Koh R.U. *et al.* Immediate implant placement: positives and negatives. *Implant Dent*, 2010, 19(2):98-108.
2. Sohn D-S. *et al.* Sticky Bone use in implant dentistry. *J Implant Adv Clinical Dent*, 2015, 7(10):11-29.
3. Kim J.Y. Preserving and maintaining optimal peri-implant soft tissue complex for function and aesthetics. *Dent Implantology Update*, 2004 15(9):65-72.

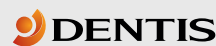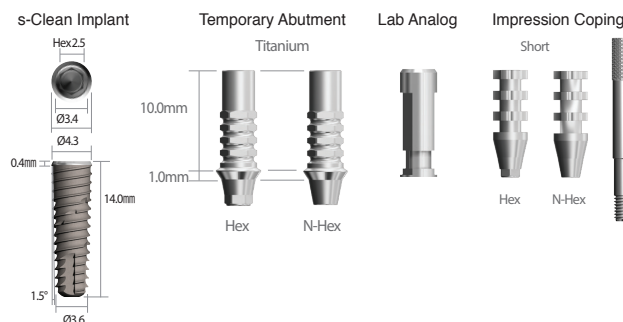
## Acknowledgment

This case was restored by Dr. Lily Namsinh, general practitioner of Garden Grove, CA USA. Laboratory dentistry was carried out by Mark Tillman, CDT, at Spectrum Dental Laboratory, Tustin CA, USA.

## Products Used

### DENTIS USA (La Palma, CA, USA)

- DENTIS™ s-Clean implant Ø4.3 x 14mm (DSFR4314S)
- Temporary abutment, 4.5mm titanium, hexed (DSTA45HS)
- Implant lab analog (DSCLA)
- Pick-Up Impression Coping 4.5mm, hex, short (DSIH45SS)



6 Centerpointe Dr. Ste. 600, La Palma, CA 90623  
Tel. 323-677-4363 | Fax. 323-677-4366 | www.dentisusa.com

### SILFRADENT (Santa Sofia FC, Italy)

- Centrifuge for CGF & “sticky bone”: Medifuge™
- Piezoelectric surgery device: Surgybone™

### Other Products

- Xenograft from Bio-Oss™, Geistlich Pharma AG, Switzerland

## LIVE-Surgery Implant Training Program

ADVANCED II (4-Day Program)

38 CEU



**GDIA**<sup>®</sup>  
Global Dental Implant Academy

Date: August 28 - 31  
December 03 - 06



World Academy of  
Ultrasonic Piezoelectric Bone Surgery



Approved PACE Program Provider  
FAGD/MAGD Credit  
Approval does not imply acceptance  
by a state or provincial board of  
dentistry or AGD endorsement  
11/1/2014 to 10/31/2017  
Provider ID# 358861



International Congress of Oral Implantologists  
Courses are applicable to ICOI advanced credentials

For more information, contact us at :

Tel. 323-617-4141 | Email. info@GDIA.com | Website. www.GDIA.com

Visit our  
website



Like us on  
Facebook

